

# Skin Responses to Fractional Photothermolysis

Hans-Joachim Laubach, MD,\* Zeina Tannous, MD, R. Rox Anderson, MD, and Dieter Manstein, MD  
Wellman Center for Photomedicine, Massachusetts General Hospital, Harvard Medical School,  
Boston, Massachusetts

**Background and Objective:** Fractional photothermolysis (FP) is a new concept using arrays of microscopic thermal damage patterns to stimulate a therapeutic response. We analyzed epidermal and dermal response to FP with the aim of correlating histological and clinical response.

**Study Design/Materials and Methods:** Twelve subjects received a single treatment with a prototype diode laser emitting at a wavelength of 1,500 nm, delivering 5 mJ per microscopic treatment zone (MTZ), and a density of 1,600 MTZs/cm<sup>2</sup> on the forearm. Biopsies were procured over a period of 3 months. The biopsies were analyzed by two blinded dermatopathologists using hematoxylin and eosin (Hematoxylin and Eosin Stain), Elastica von Gieson, nitro-blue-tetrazolium-chloride (NBTC) viability, and immunohistochemistry stains. Furthermore, the treatment sites were evaluated *in vivo* by confocal microscopy.

**Results and Discussion:** Twenty-four hours after fractional photothermolysis, the continuity of the epidermal basal cell layer is restored. Complete epidermal regeneration is obtained 7 days after the treatment. Microscopic epidermal necrotic debris (MENDs) are seen as early as 1 day after FP. MENDs contain melanin pigment, and are shed from the epidermis within 7 days. Evidence of increased collagen III production is shown with immunohistochemistry (IHC) staining 7 days after FP. IHC for heat shock protein 70 (HSP 70) shows the expression of HSP 1 day after FP, and IHC for alpha smooth muscle actin shows the presence of myofibroblasts 7 days after FP. These findings are concordant with the induction of a wound healing response by FP. There is no evidence of residual dermal fibrosis 3 months after treatment.

**Conclusion:** A single treatment with fractional photothermolysis induces a wound healing response in the dermis. A mechanism for the precise removal of epidermal melanin is described, in which MENDs act as a melanin shuttle. *Lasers Surg. Med.* 38:142–149, 2006.

© 2006 Wiley-Liss, Inc.

**Key words:** ablative resurfacing; confocal microscopy; fractional resurfacing; fractional photothermolysis; histology; human; immunohistochemistry; *in vivo*; laser; melanin shuttle; microscopic epidermal necrotic debris, MEND; Microthermal zones, MTZ; non-ablative resurfacing; non-ablative remodeling; skin rejuvenation

## INTRODUCTION

Non-ablative dermal remodeling and ablative skin resurfacing are currently well-established treatment modalities for the repair of photoaged skin. Ablative skin resurfacing with CO<sub>2</sub> or Er:YAG laser removes the entire epidermis of the treatment area. This is generally considered to be the most effective laser treatment option for the repair of photodamaged tissue, but patients sometimes experience significant side effects after the treatment. Especially long lasting pigmentary changes, infection, and scarring are unacceptable for many patients [1,2]. Non-ablative laser and intense-pulse-light systems are currently used as an alternative to tighten the skin without harming the epidermis. In this technique, controlled dermal heating without epidermal damage is achieved by combining the laser or intense-pulsed-light treatment with simultaneous skin surface cooling. The selective thermal damage of the dermis is followed by wound healing response of the damaged tissue ultimately leading to new collagen formation. The absence of epidermal damage decreases the severity and amount of side effects associated with the treatment. However, the major disadvantage of this technique is the limited efficacy compared to ablative laser skin resurfacing [3–5].

Fractional photothermolysis (FP) was recently introduced by Manstein et al. [6] as a new concept for laser skin rejuvenation to address the drawbacks of both, ablative skin resurfacing with its significant side effects and non-ablative dermal remodeling with its limited efficacy. In FP, a near infrared 1,500-nm laser light, which is mainly absorbed by aqueous tissue, creates a dense pattern of epidermal and dermal microscopic thermal wounds (referred

---

Abbreviations: MTZ, Microthermal zone; MEND, microscopic epidermal necrotic debris; IHC, immunohistochemistry; FP, fractional photothermolysis; NBTC, nitro-blue-tetrazolium chloride; HSP, heat shock protein; PCNA, proliferating cell nuclear antigen; PIH, post inflammatory hyperpigmentation.

R.R.A has disclosed a potential financial conflict of interest with this study.

\*Correspondence to: Hans-Joachim Laubach, MD, Massachusetts General Hospital, Wellman Center for Photomedicine, BAR #305, 50 Blossom Street, Boston, MA 02114.

E-mail: hlaubach@partners.org

Accepted 15 September 2005

Published online 3 January 2006 in Wiley InterScience

(www.interscience.wiley.com).

DOI 10.1002/lsm.20254

to as Microthermal zones (MTZ)) and characteristically spares the tissue that surrounds each MTZ. Typically a density of 1,000–2,000 MTZs per square centimeter is achieved.

The purpose of this study is to investigate if FP, creating a unique pattern of microscopic thermal lesions, still induces a wound healing response in the human skin. Furthermore, we want to examine the effect of this new treatment modality on the formation of new collagen in the dermis. Additionally exploring the effect of FP on elastic fibers is of great interest since solar elastosis is one of the most prominent histological findings in dermatoheliosis. To answer those questions, we investigated the pathophysiological mechanisms that are involved in FP using common histological staining methods, immunohistochemistry, and *in vivo* confocal microscopy.

## MATERIALS AND METHODS

### Study Subjects

Twelve healthy volunteers with no known history of keloid formation, isotretinoin use within the last 6 months, current systemic infection, or previous laser treatment of the area to be treated were enrolled in this study. The subjects had multiple Fitzpatrick skin types (II–VI), and ranged between 24 and 64 years of age. Test sites of  $8 \times 8$  mm<sup>2</sup> in size were placed at the inner forearm of each subject and were mapped with four microtattoos at the corners of each site. No cooling or analgesia was used before the exposure.

To understand the immediate and long-term skin response to FP biopsies were performed at 1 hour and 1, 3, 5, and 7 days and 3 months after the exposure. The time points of biopsies were randomly assigned to each subject. Subjects had a maximum of four biopsies each including one control biopsy; control biopsies were taken at 3 months after exposure from unexposed areas that were adjacent to the treated sites.

### Laser

A laser prototype device (Reliant Technologies, Inc., Palo Alto, CA), which emits a wavelength of 1,500 nm, was used to provide a distinct and well-defined pattern of micro-exposures at a distance of 250 microns from the center of the individual MTZs. This correlates with 1,600 lesions per square centimeter. A constant energy of 5 mJ per MTZ was used.

### Confocal Microscopy

A commercially available confocal microscope (Viva-scope1000<sup>®</sup>, Lucid-Tech, Inc., Henrietta, NY) was employed to image some of the laser-treated sites. A detailed description of this device has been published elsewhere [7]. The treatment sites were analyzed continuously for up to 6 hours after exposure, and a systematic horizontal mapping was obtained. Four to six images were captured in axial sections of the stratum corneum, epidermis, and up to the upper reticular dermis. The images were then individually evaluated.

### Histology

The excised skin was fixed in 10% formalin and embedded in paraffin. Three-micrometer thick sections were stained with hematoxylin and eosin (H&E), and Elastica von Gieson stains were prepared for histological analysis. Samples intended for NBTC viability staining were processed separately for frozen sections. NBTC staining was performed as described by Chung et al. [8]

Immunohistological (IHC) staining was performed to detect proliferating cells using proliferating cell nuclear antigen (PCNA, BioGenex, San Ramon, CA), myofibroblasts using alpha-smooth muscle actin ( $\alpha$ -SMA, BioGenex, San Ramon, CA), new collagen formation using Collagen type III (BioGenex, San Ramon, CA), and physical stress on tissue using heat shock protein 70 (HSP 70, BioGenex, San Ramon, CA).

Immunohistochemistry staining was performed according to the standard routine techniques as supplied by the manufacturer (BioGenex, San Ramon, CA).

Two pathologists who are experienced in the area of skin pathology and cutaneous laser treatment analyzed the sections independently.

## RESULTS

### Confocal Microscopy

*In vivo* confocal microscopy reveals a complete loss of dermal reflection in the MTZs immediately after FP. However, there is an increase of reflection throughout the epidermal portion of the MTZs. There is evidence of an increase in reflectance of the stratum corneum after the treatment. The dermo-epidermal junction reveals a sub-epidermal reflection loss immediately after the exposure. The size of the area of subepidermal reflection loss increases over the next 6 hours (Fig. 1).

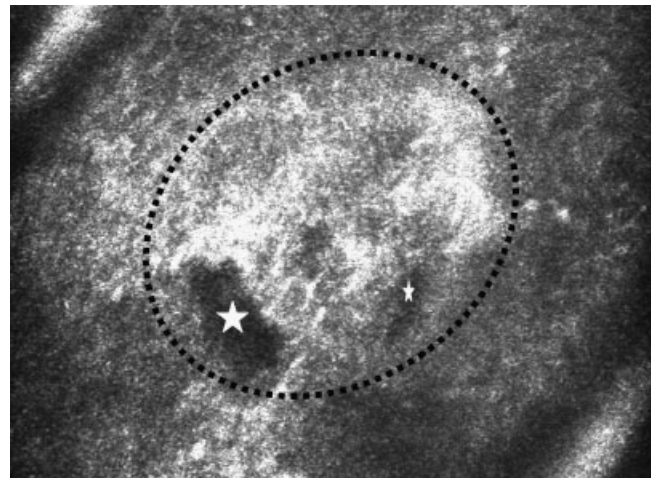


Fig. 1. Hour 6 after FP—in *in vivo* confocal microscopy. A horizontal cut-through dermo-epidermal junction shows areas of reflection loss (white stars) in the MTZ (black outline).

### One Hour After FP (Hematoxylin and Eosin Stain)

Biopsies that were taken one hour after FP reveal an intact stratum corneum with a normal basket-wave appearance and no evidence of structural alterations. A well-defined underlying column of epidermal and dermal thermal damage is noted, and is referred to as the Microthermal zone (MTZ).

The epidermal damage is predominantly in the lower half of the epidermis, which leads to disruption of the dermo-epidermal junction and the beginning of the formation of sub-epidermal clefting. No inflammatory infiltrate is yet seen in the region surrounding the MTZs (Fig. 2a). Vessels that are located within the individual MTZs appear to be thermally coagulated without concomitant hemorrhage into the surrounding tissue (Fig. 2b).

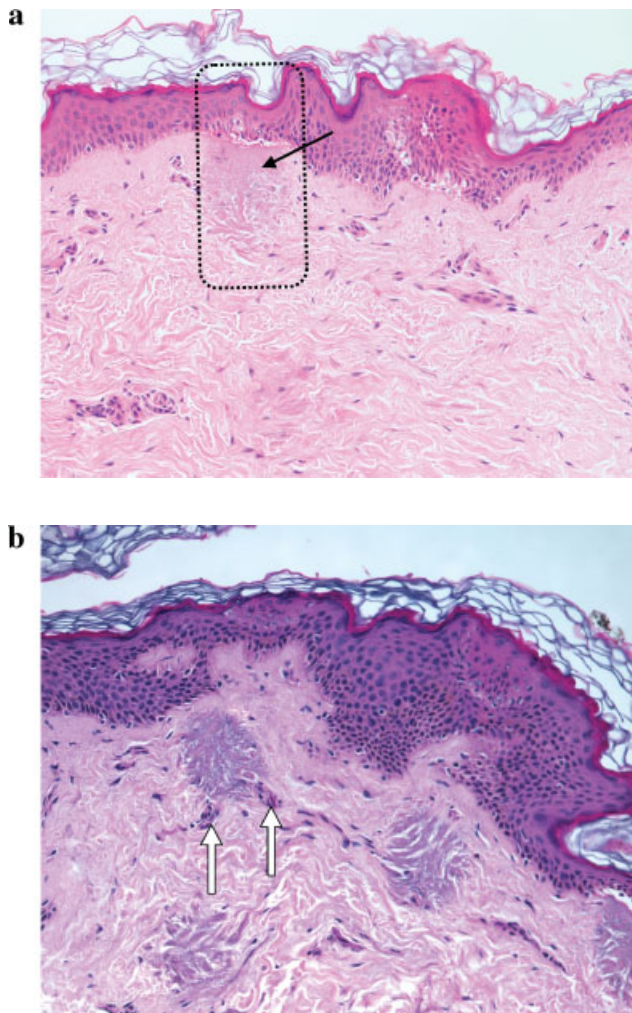


Fig. 2. **a:** Hour 1 after FP (200 $\times$  H&E). Microthermal zones (MTZ, black outline) with columns of altered collagen (black arrow) can be distinguished. The entire stratum corneum remains intact even above the epidermal MTZs. There is no inflammatory infiltrate around the dermal MTZs yet. **b:** Hour 1 after FP (200 $\times$  H&E) vessels in the MTZs are thermally destroyed (white arrows).

### One Day After FP (Hematoxylin and Eosin Stain)

Although the dermal part of the MTZ appears unchanged, there are marked morphological changes within the epidermis.

Day 1 marks the formation of microscopic epidermal necrotic debris (MENDs), which is thought to represent the elimination of the thermally damaged keratinocytes through the migration of the viable keratinocytes that are present at the margins of the wound. The MENDs reside in the epidermis in a sub-granular location, and contain a substantial amount of pigment. Fontana Masson stain confirms the presence of melanin pigment within the MENDs in higher density than in the surrounding epidermis. The basal cell layer that underlies the MENDs appears to be melanin deprived but continuous. Scattered dyskeratotic cells in the epidermis are seen in close approximation to the MTZs and in the surrounding MENDs.

Subepidermal clefting is now more pronounced in the area of the MTZ and overlies a well-defined zone of homogenized collagen. A subtle inflammatory infiltrate is present predominantly around the vascular structures that surround the MTZs (Fig. 3).

### Three Days After FP (Hematoxylin and Eosin Stain)

The MENDs have exited the epidermis and are now sandwiched between the epidermis and the stratum corneum. The epidermis demonstrates dyskeratotic cells and spongiosis. The subepidermal clefting is regressing, and only small residual clefts are observed. A well-defined cone of homogenized collagen can still be seen in the dermis.

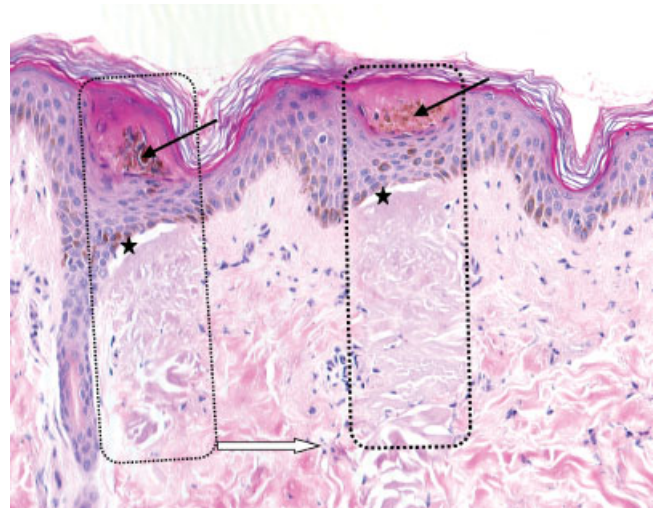


Fig. 3. Day 1 after FP (200 $\times$  H&E). MTZs are outlined in black. Microscopic epidermal necrotic debris (MENDs; black arrows) represents the elimination of thermally damaged keratinocytes. MENDs are loaded with melanin. Subepidermal clefting is evident from 1 hour after FP and lasts up to 5 days (stars). The dermal part of the MTZs appears unchanged from day 1, and shows thermally altered collagen and a lack of nuclear staining. Subtle perivascular inflammatory infiltrate begins to form in the dermis (white arrow).

### Five Days After FP (Hematoxylin and Eosin Stain)

The MENDs are now floating within the stratum corneum. A few dyskeratotic keratinocytes and minimal spongiosis can still be observed in the epidermis. There is no evidence of residual subepidermal clefting. Zones of homogenized dermis are still present, and are associated with minimal—predominantly lymphocytic—perivascular dermal inflammation.

### Seven Days After FP (Hematoxylin and Eosin Stain)

The MENDs are either intracorneal or have already shed off. The epidermis is otherwise normal in appearance, and shows a well-developed architecture with normal to increased epidermal thickness and a normal rete ridge pattern with no dyskeratosis, spongiosis, or clefting.

The dermis still reveals cones of thermally altered collagen. There is a regressing inflammatory infiltrate with occasional foci of new vascular formation surrounding and infiltrating the MTZs (Fig. 4).

### Three Months After FP (Hematoxylin and Eosin Stain)

There is no evidence of dermal fibrosis or residual cones of altered collagen. Furthermore, there is no evidence of residual inflammatory infiltrate. The MTZs can no longer be seen with standard H&E staining.

### Elastica Von Gieson

There is no noted difference in the quantity or the arrangement of elastic fibers, as demonstrated with von Gieson stain, at any given point in the study. The elastic fibers retain their characteristic candelabra structure after FP (Fig. 5).

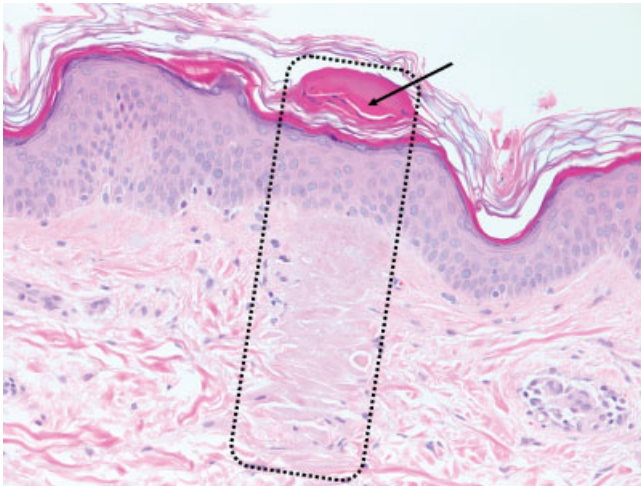


Fig. 4. Day 7 after FP (200× H&E). MENDs are intracorneal or have shed off (black arrow). The epidermis is free of dyskeratosis and spongiosis. There is no evidence of residual clefting in the dermo-epidermal junction. The dermal MTZs (black outline) still show cones of thermally altered collagen, but they are less well defined.

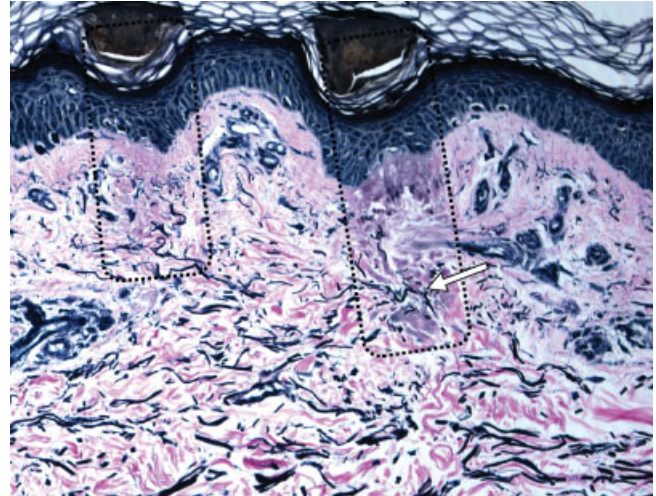


Fig. 5. Day 7 after FP (200×—Elastica von Gieson). The regular candelabra arrangement of elastic fibers persists at all times after FP (white arrow). MTZs are outlined in black.

### Nitro-Blue-Tetrazolium Chloride (NBTC) Viability Stain

The NBTC stain reveals a loss of viability in the epidermis and the dermis at 1 hour after FP. One day after the exposure the dermis shows a continuous layer of viable cells overlying dermal zones of loss of viability (Fig. 6). These zones become less and less well defined in the biopsies from Day 3 to Day 7. Three months after FP, a continuous viability staining of both the epidermis and the dermis can be found.

Please note that the stratum corneum never stains positive for NTBC in normal epidermis.

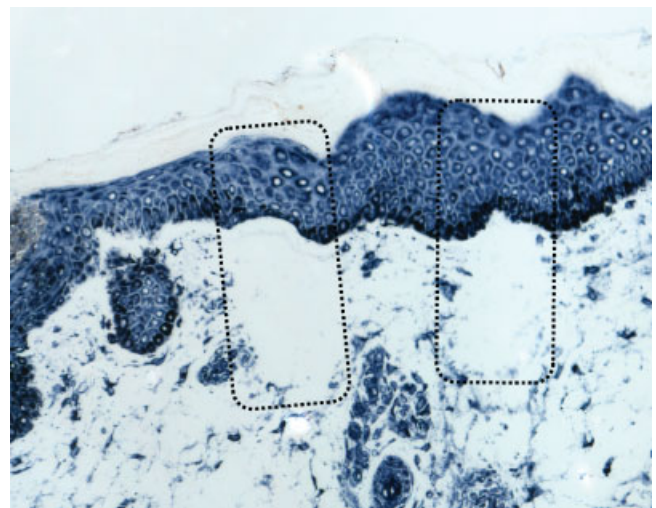


Fig. 6. Day 1 after FP (200×—NBTC viability stain). MTZs (black outline) consist of viable epidermis overlying dermal cones with complete loss of viability.

### Heat Shock Protein (HSP) 70

There is no evidence of increased HSP 70 expression 1 hour after FP. An increase in HSP 70 staining is detected only on the first day after FP exposure. Biopsies performed three days and later after FP did not show any evidence of increased HSP 70 expression.

In the biopsies from one day after FP there is a strong increase in HSP 70 concentration in the epidermis, particularly within the areas that underlie the MENDs. There is also a complete loss of HSP 70 expression in the dermal MTZs themselves, but a strong increase in expression in the tissue that surrounds the MTZs (Fig. 7).

### Collagen III

Immunohistochemistry studies show a complete absence of staining for collagen III one hour after the treatment inside the dermal MTZs, which suggests the thermal alteration of collagen III. Collagen III staining gradually increases from the first to the seventh day after FP exposure. It is more prominent in the dermis that surrounds the MTZs, with the highest intensity being seen in the dermis that underlies the MTZs (Fig. 8).

There is no evidence of altered dermal collagen III staining 3 months after FP.

### Proliferating Cell Nuclear Antigen (PCNA)

An increase in epidermal PCNA expression is noted up to 9 days after FP. There is no difference in the epidermal expression of PCNA between the treated sites and the

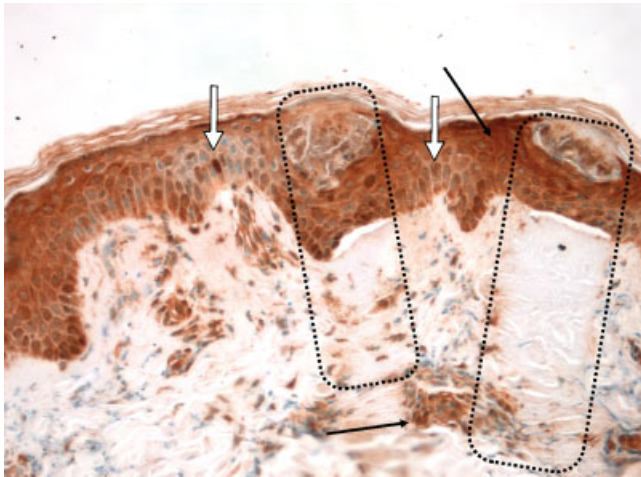


Fig. 7. Day 1 after FP (200 $\times$ —immunohistochemistry for HSP 70 with underlying NTBC viability stain). The overall HSP 70 expression is increased in the dermis and epidermis compared to 1 hour and 3 days after FP. The areas underlying the MENDs in the epidermis and surrounding the MTZs in the dermis show the most pronounced expression (black arrows). A decrease in HSP 70 expression is seen in the area surrounding the epidermal MTZs (white arrows). There is a complete absence of HSP 70 expression in the dermal MTZs (black outline). Compared to one day after FP, there is no increase in HSP 70 expression 1 hour or 3 days after FP.

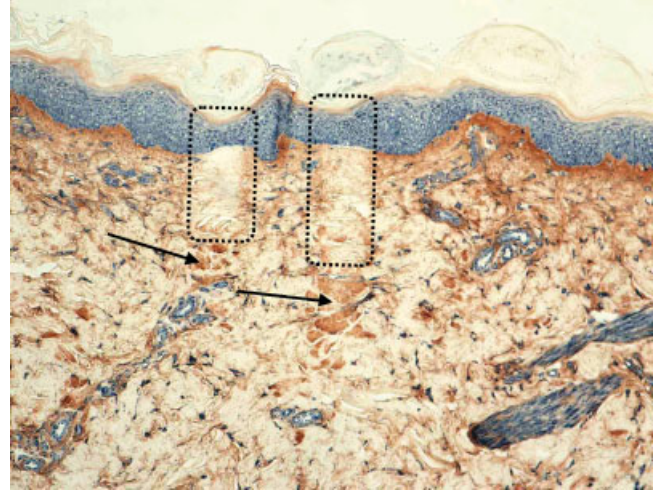


Fig. 8. Day 7 after FP (100 $\times$ —immunohistochemistry for collagen III with underlying NTBC viability stain). Collagen III expression increases in the periphery of the MTZs, particularly below the MTZs (black arrows). Collagen III expression is absent in the dermal MTZs (black outline).

control sites 3 months after FP. No difference in the dermal expression of PCNA can be detected at any time after FP.

### Alpha-Smooth Muscle Actin

The foci of new vessel formation in the dermis surrounding the MTZs are demonstrated by  $\alpha$ -SMA stain 7 days after FP. These foci partially infiltrate the dermal MTZs.

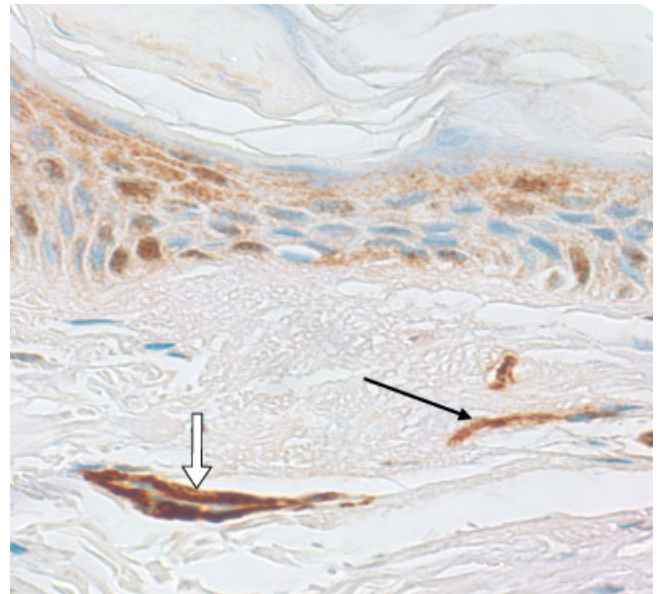


Fig. 9. Day 7 after FP (400 $\times$ —immunohistochemistry for alpha smooth muscle actin with underlying NTBC viability stain). Myofibroblasts (actin-containing fibroblasts) can be seen on day 7 after FP (black arrow). There is evidence of increased vasculature around the MTZs (white arrow).

Furthermore, myofibroblasts, which are fibroblasts that contain actin, can also be seen at 7 days after FP (Fig. 9).

### Miscellaneous

Occasional dermal melanophages were detected 3 months after FP in one subject with Fitzpatrick skin type VI.

## DISCUSSION

FP was recently introduced as a new concept of laser-tissue interaction by Manstein et al. [6]. In this study, we histologically investigated the *in vivo* effects of this new treatment modality on human skin. The laser-treated sites were evaluated with standard H&E stains; special stains, such as Elastica von Gieson; NTBC viability; IHC studies; and confocal microscopy.

The confocal microscopy study affirmed that the subepidermal clefting seen in the histological analysis does correlate with a subepidermal reflection loss *in vivo*. Hence the clefting an *in vivo* phenomenon and does not represent a histological preparation artifact. Furthermore, confocal microscopy reveals a complete loss of dermal reflection in the MTZs immediately after FP. This is based most likely on the thermal denaturation and the resulting change of optical properties of dermal collagen [7,9,10].

Probably the most prominent epidermal effect that is induced by FP is the formation of MENDs and their timed migration within the epidermal layers. The process of elimination of necrotic epidermal cells forms the MENDs, and they are noted as early as 24 hours after the FP treatment (Fig. 3). In how far dermal necrotic debris is part of the MENDs cannot be determined at this point. The MENDs are located in the epidermis just below the granular cell layer at day one, and thus correlates clinically with the onset of bronzing, as noted by patients at day one, that is secondary to the high melanin content of the MENDs. At day 3, the MENDs have migrated through the epidermis and lie just below the stratum corneum, which correlates with the clinical onset of flaking that is generally noticed by patients at day three. Flaking occurs due to the elimination of the MENDs from the stratum corneum, and becomes more prominent on days 5–7 after FP due to the ease of elimination of the MENDs when they are located in the middle and superficial layers of the stratum corneum (Fig. 4). MENDs have rich melanin content as seen in the H&E stain (Fig. 3). Furthermore, the underlying newly formed basal cell layer exhibits a decrease in melanin content, and it appears that the melanin pigment that was previously present in the basal cell layer is now a part of the MENDs, which are loaded with melanin, and is transported by the MENDs through the epidermis. Thus, the MENDs act as “melanin shuttle” (Fig. 3). The upward movement of the MENDs may be the result of the rapid migration of keratinocytes from the borders of the epidermal MTZs. This process leads to the elimination of melanin from the epidermis and is most likely the reason for the lightening of lentigines and melasma after FP treatment.

Due to the remaining undamaged stratum corneum and the multiple layers of necrotic keratinocytes above the dermis (Figs. 2a and 3), it is expected that the epidermal barrier function remains intact after FP. We would like to remark that this is the finding for settings used in this particular study. We believe that a perforation of the stratum corneum can be obtained with higher energies than used in this study. Twenty-four hours after FP, healthy keratinocytes have replaced the thermally damaged keratinocytes in the epidermis (Fig. 6), which closes an area with a lack of viability stain that was evident 1 hour after FP. These two findings together explain the minimal risk of infection, oozing, or macroscopic crusting with this new treatment modality.

Day 7 after FP marks the apparently complete normalization of the epidermis with no residual dyskeratosis, spongiosis, or subepidermal clefting (Fig. 4), which indicates complete epidermal healing. We, therefore, suggest a treatment interval of at least 1 week for common applications of FP to allow enough time for the adequate regeneration of the epidermis. Shorter intervals may be warranted for indications outside of the current routine use of FP.

Collagen remodeling and formation after non-ablative and ablative resurfacing is thought to be a primary component in the reduction of rhytides and the improvement of skin texture. Some authors report evidence of new collagen formation as detected by the evaluation of regular H&E stain or orcein stain after non-ablative resurfacing [11–14]. After consultation with several independent dermatopathologists, we are hesitant to draw this conclusion from the evaluation of the collagen alignment in the H&E stained tissue sections alone. The total absence of IHC staining for collagen III inside the dermal MTZs 1 hour after the treatment corresponds to the thermal denaturation of collagen III. Subsequently, collagen III staining increases around and especially below the MTZs up to 7 days after exposure (Fig. 7). There is no evidence of decreased collagen III staining throughout the dermis 3 months after exposure, which shows that thermally damaged collagen inside the MTZ is completely replaced with new collagen after 3 months. These findings suggest the formation of new collagen in the dermis in and around the MTZ, which is an expected wound healing response.

Sublethal thermal stress to human tissue *in vivo* leads to the expression of HSPs. HSP 70 belongs to a group of proteins called chaperons preserving the cell integrity in sublethally damaged cells by stabilizing the proper 3D-folding of proteins. It assists in protein folding, and allows the functional state of proteins to be maintained under conditions, such as thermal stress, under which they would normally unfold and aggregate. This damage would ultimately lead to apoptosis of the cell. HSP 70 also plays a role in inducing the expression of other growth factors, such as transforming growth factor (TGF)-beta, which is a key element in the wound healing response and the fibrogenic process. The dermal part of the MTZ itself is free of any HSP 70 expression due to the absence of viable cells in these areas, which confirms the results of the NBTC

viability stain. Furthermore, there is an increase in the HSP 70 expression in the tissue surrounding the dermal MTZs (Fig. 6). This suggests sublethal damage to the fibroblast and the production of HSP 70 in the border zone of the dermal MTZs, which then induces a wound healing response in the dermis.

IHC staining for alpha smooth muscle actin detects scattered myofibroblasts (Fig. 8), which corresponds to the dermal wound healing response that is described by Gabbiani et al. [15–18]. These myofibroblasts are one of the main forces behind the mechanism of wound contraction, and could induce additional skin tightening. We hypothesize that MTZs that are created by FP induce a wound healing response with the deposition of new collagen and an increase in dermal collagen remodeling. Further studies with objective measurements of the dermal remodeling process after FP as carried out by Orringer et al. for CO<sub>2</sub> laser resurfacing are warranted.

The gold standard for skin rejuvenation is still ablative resurfacing with CO<sub>2</sub> or Er:YAG laser. The wound healing response that is induced by ablative resurfacing is always followed by the development of a variable degree of superficial dermal fibrosis in the treated region [1]. Depending on the degree of this intradermal fibrosis, the optical properties of the skin change. Ultimately these changes can result in a cosmetically unpleasant porcelain white hypopigmentation of the treated area, particularly in light-skinned individuals, which leaves the patient with an unnatural appearance. It still remains to be determined whether some degree of fibrosis in the dermis is desirable to create a cosmetically appealing result. In this histological study, we did not find any evidence of dermal fibrosis 3 months after FP. Please note that these findings relate to a single FP treatment. Serial treatments with FP may induce dermal fibrosis, and further studies are, therefore, warranted to observe the histological changes after serial treatments with FP.

The increase in elastic fibers is an important contributor to the findings on dermatoheliosis. Although collagen denaturation is demonstrated in MTZs, there is no evidence of a change in the morphology or the content of the elastic fibers after FP (Fig. 5). These findings indicate that FP with the settings that were used in this study has no direct effect on elastic fibers. As all of the biopsies were taken from the UV-protected surface of the inner forearm, none of them showed the elastin sheets that characterize solar elastosis. Additional histological studies from UV-exposed areas are needed to demonstrate the effects of FP on the altered elastin that is present in solar elastosis. Future studies are also needed to investigate whether modification of the exposure parameters, such as an increase in energy per MTZ, leads to a different effect on the elastic fibers.

Another important component of dermatoheliosis is the formation of teleangiectasias. Interestingly, the emitted wavelength in FP is not selectively absorbed by blood-containing targets, and thus does not provide selective photothermolysis to the blood vessels. However, by creating a multitude of zones of intense thermal damage in the upper dermis, FP may non-selectively coagulate vessels in

the upper dermis (Fig. 2b). Therefore, segments of vessels in the area of the MTZs are sealed, which compromises the blood flow of the entire vessel. This histological finding correlates very well with anecdotal reports of a decrease in teleangiectasias after FP treatment. FP may, therefore, offer a new method for targeting blood vessels when the distribution of vessels and the thermal damage pattern are well matched.

An especially troublesome side effect of ablative laser resurfacing is the induction of postinflammatory hyperpigmentation (PIH). It is striking to see the marked localized thermal damage that is induced by FP, which is associated only with relatively mild inflammation. This may be explained by the characteristic microscopic nature of the damage pattern that is produced by FP, which leads to minimal inflammation and thus a lower incidence of clinically evident PIH. Although none of the subjects in this study experienced clinically evident PIH, one biopsy from a patient with Fitzpatrick skin type VI revealed a few scattered dermal melanophages in the treatment area 3 months after FP. This is most likely to be a histological equivalent to sub-clinical PIH. The absence of clinically evident PIH in our study patients suggests a lower risk of PIH development after FP compared to standard ablative resurfacing. However, the presence of melanophages in the dermis of one patient suggests that a possibility of developing PIH after FP, especially in patients with darker skin types, remains.

This study was performed with a prototype device that delivers a very regular pattern of FP. The currently commercially available devices (Fraxel™) applies the MTZ pattern in multiple passes and deliver a statistically randomized treatment pattern. This implies that the distance between individual MTZs is not well defined, although the average MTZ density is defined. Furthermore, an irregular pattern may be produced, which may ultimately result in an alteration in the response of the epidermis and the dermis to FP. A quantitative analysis of the patterns and biological wound healing that is achieved with commercially available devices requires further study.

Future applications of FP might involve the treatment of Poikiloderma of Civatte by its ability to treat dyschromia along with teleangiectasias; the treatment of melasma by its ability to remove epidermal pigment with the help of the “Melanin Shuttle,” and the possible combination with topical agents as a way to profit from synergistic effects of laser and drug therapy.

## CONCLUSION

FP induces a wound healing response in the dermis by the creation of a new thermal damage pattern. The epidermis recovers fast and apparently completely within 7 days after the treatment. The thermally damaged collagen inside the MTZ is completely replaced with new collagen within 3 months. No evidence of dermal fibrosis is observed after a single FP treatment in this 3-month follow up study. Additionally FP appears to randomly coagulate small blood vessels in the papillary dermis.

The precise removal of epidermal pigment is possible, as the MENDs act as a melanin shuttle. The clinically observed lightening of epidermal pigmentation is probably secondary to the redistribution and partial release of epidermal melanin as a result of MENDs migration.

## REFERENCES

- Ross EV, Miller C, Meehan K, et al. One-pass CO<sub>2</sub> versus multiple-pass Er:YAG laser resurfacing in the treatment of rhytides: A comparison side-by-side study of pulsed CO<sub>2</sub> and Er:YAG lasers. *Dermatol Surg* 2001;27:709–715.
- Hruza GJ. Laser skin resurfacing. *Arch Dermatol* 1996;132:451–455.
- Goldberg DJ, Whitworth J. Laser skin resurfacing with the Q-switched Nd:YAG laser. *Dermatol Surg* 1997;23:903–906.
- Herne KB, Zachary CB. New facial rejuvenation techniques. *Semin Cutan Med Surg* 2000;19:221–231.
- Menaker GM, Wrone DA, Williams RM, et al. Treatment of facial rhytides with a nonablative laser: A clinical and histological study. *Dermatol Surg* 1999; 25:440–444.
- Manstein D, Herron GS, Sink RK, Tanner H, Anderson RR. Fractional photothermolysis: A new concept for cutaneous remodeling using microscopic patterns of thermal injury. *Lasers Surg Med* 2004;34:426–438.
- Rajadhyaksha M, Gonzalez S, Zavislan JM, Anderson RR, Webb RH. In vivo confocal scanning laser microscopy of human skin II: Advances in instrumentation and comparison with histology. *J Invest Dermatol* 1999;113:293–303.
- Chung JH, Koh WS, Youn JL. Histological responses of port wine stains in brown skin after 578 nm copper vapor laser treatment. *Laser Surg Med* 1996;18:358–366.
- Gonzalez S, Gonzalez E, White WM, Rajadhyaksha M, Anderson RR. Allergic contact dermatitis: Correlation of in vivo confocal imaging to routine histology. *J Am Acad Dermatol* 1999;40:708–713.
- Selkin B, Rajadhyaksha M, Gonzalez S, Langley RG. In vivo confocal microscopy in dermatology. [review] [26 refs]. *Dermatol Clin* 2001;19:369–377.
- Fournier N, Dahan S, Barneon G, et al. Nonablative remodeling: A 14-month clinical ultrasound imaging and profilometric evaluation of a 1540 nm Er:Glass laser. *Dermatol Surg* 2002;28:926–931.
- Fournier N, Dahan S, Barneon G, et al. Nonablative remodeling: Clinical, histologic, ultrasound imaging, and profilometric evaluation of a 1540 nm Er:Glass laser. *Dermatol Surg* 2001;27:799–806.
- Sarradet MD, Hussain M, Goldberg DJ. Electrosurgical resurfacing: A clinical, histologic, and electron microscopic evaluation. *Lasers Surg Med* 2003;32:111–114.
- Lee MW. Combination 532-nm and 1064-nm lasers for noninvasive skin rejuvenation and toning. *Arch Dermatol* 2003;139:1265–1276.
- Gabbiani G, Le Lous M, Bailey AJ, Bazin S, Delaunay A. Collagen and myofibroblasts of granulation tissue. A chemical, ultrastructural and immunologic study. *Virchows Arch B Cell Pathol* 1976;21:133–145.
- Gabbiani G, Badonnel MC. Contractile events during inflammation. *Agents Actions* 1976;6:277–280.
- Gabbiani G. The myofibroblast in wound healing and fibrocontractive diseases. [review] [20 refs]. *J Pathol* 2003; 200:500–503.
- De Freitas AC, Pinheiro AL, de Oliveira MG, Ramalho LM. Assessment of the behavior of myofibroblasts on scalpel and CO(2) laser wounds: An immunohistochemical study in rats. *J Clin Laser Med Surg* 2002;20:221–225.